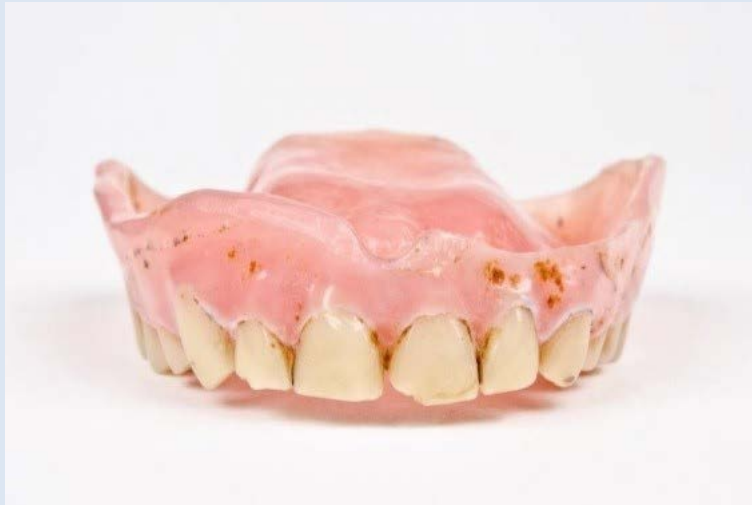

## Communication Task 1 - dentist

Mrs Cooper is 80 years-old and is a new patient to your practice. Last week Mrs Cooper came and spoke with your receptionist, Sarah, telling her that she has been wearing complete dentures for about 20 years, but that her dentures are now looking very stained and dirty. Mrs Cooper had handed her upper denture to Sarah in a bag and asked Sarah to pass them on to you, the dentist, for cleaning. Sarah showed you the denture below.



You asked Sarah to return the denture to Mrs Cooper and to book Mrs Cooper in for a consultation; Mrs Cooper is attending for her consultation today.

You review her medical history form. There is nothing noted except that Mrs Cooper has written that she sometimes has difficulty hearing.

**You have 10 minutes for this consultation. You should find out more about Mrs Cooper and her presenting complaint with the aim of gaining consent for a clinical examination.**

An examiner will escort you into the consultation room and will observe the consultation.

A second examiner will be acting as the patient and will occasionally ask you a question. You should assume that they are a regular dental patient with limited dental knowledge. You should speak to them as a patient and not as an examiner with expert dental knowledge.

You will be reminded when there is one minute left before the end of the task and you should then close the consultation appropriately.

## Communication task 2 - dentist

Mr Bruce Grant is a long-standing patient of the practice where you recently started work. His last check-up was over 12 months ago. He has attended this morning for a scale and clean with Rob, the hygienist, and has complained to him of a lost filling.

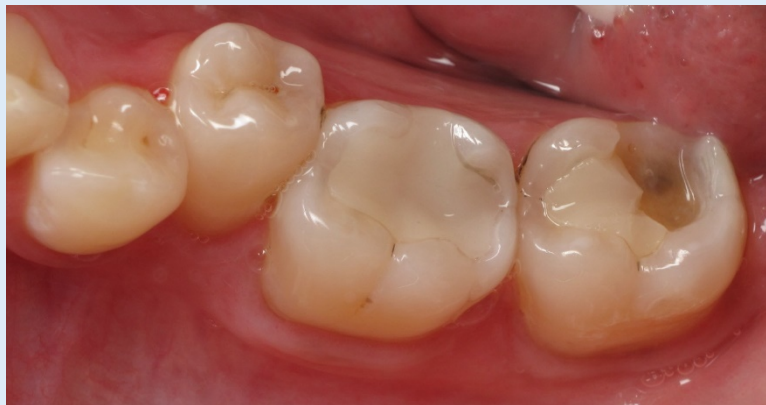Mr Grant has requested immediate treatment. His tooth is not painful, but his tongue is sore and he is travelling interstate to a conference this afternoon where he is giving a presentation.

Rob has asked Jane, the receptionist, to book a 15 minute emergency appointment for Mr Grant. Jane has booked Mr Grant in with you mid-morning as you are the new dentist at the practice and you are building up your patient list. You have another patient booked in for a 90 minute crown preparation appointment immediately afterwards. You have not seen Mr Grant before.

You speak briefly with Rob who tells you that Mr Grant is generally fit and well and he describes the lost restoration on tooth 37 as shown in the photograph below.

**You should plan to provide a temporary restoration today.** (You do not need to perform a clinical examination during this task).

**You have 10 minutes for this consultation. You should guide the consultation towards obtaining consent for your suggested treatment plan.**



An examiner will escort you into your surgery and will observe the consultation.

A second examiner will be acting as the patient and will occasionally ask you a question. You should assume that they are a regular dental patient with limited dental knowledge. You should speak to them as a patient and not as an examiner with expert dental knowledge.

You will be reminded when there is one minute left before the end of the task and you should then close the consultation appropriately.

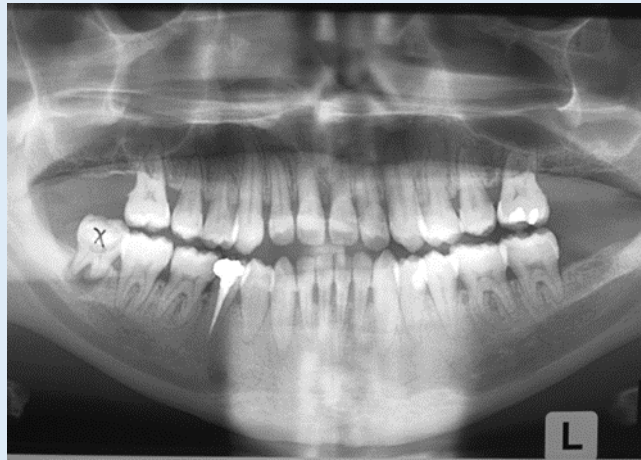
## Communication Task 3 - Dentist

Mrs Wilson is 45 years-old and is a new patient to your practice.

She attends today requesting a scale and clean as her previous dentist of 20 years has recently retired.

You note that Mrs Wilson's medical history is clear but she reports that she smokes 10 cigarettes a day and has a family history of early tooth loss.

Mrs Wilson has brought along an orthopantomograph (OPG), taken at her last dental appointment where she had tooth 48 extracted.



Today, you have performed a full examination including periodontal charting. You find heavy plaque and calculus deposits and extrinsic staining, with some bleeding on probing at deeper sites. You record generalised probing depths of 5-6mm and recession of up to 2mm on the lower anterior teeth.

You diagnose generalised chronic moderate periodontal disease, with some localised severe sites.

**You have 10 minutes for this consultation.**

**Explain your diagnosis to Mrs Wilson and work towards gaining informed consent for your periodontal treatment plan.**

An examiner will escort you into the consultation room and will observe the consultation.

A second examiner will be acting as your patient and will occasionally ask you a question. You should assume that they are a regular dental patient with limited dental knowledge. You should speak to them as a patient and not as an examiner with expert dental knowledge.

You will be reminded when there is one minute left before the end of the task and you should then close the consultation appropriately.

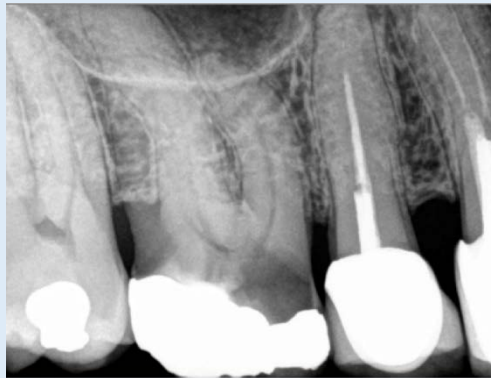## Communication Task 4 - Dentist

Mr/Mrs Kumar is 45 years-old with a clear medical history but smokes 15 cigarettes per day.

He/she attended yesterday complaining of pain in the upper right quadrant that has been getting worse over the last few nights.

At that appointment you performed an intraoral examination which revealed a large amalgam restoration on tooth 16. Tooth 16 was also tender to percussion and palpation and was non-responsive to cold thermal testing.

You took a periapical radiograph which demonstrated a widening of the periodontal ligament space at the apex of the 16 mesiobuccal root canal with some evidence of calcific changes in the pulp chamber. You diagnosed irreversible pulpitis of the 16. You have explained the diagnosis, treatment options, along with the risks and costs to Mr/Mrs Kumar, and he/she has given consent for endodontic treatment on tooth 16.



Today Mr/Mrs Kumar is attending for commencement of the endodontic treatment on tooth 16.

You have started endodontic treatment but have encountered a problem and have halted the procedure to speak to Mr/Mrs Kumar.

**Details of the problem will be provided at the communication reading station for you to pre-read. You have 10 minutes for this consultation.**

An examiner will escort you into the consultation room and will observe the consultation.

A second examiner will be acting as your patient and will occasionally ask you a question. You should assume that they are a regular dental patient with limited dental knowledge. You should speak to them as a patient and not as an examiner with expert dental knowledge.

You will be reminded when there is one minute left before the end of the task and you should then close the consultation appropriately.

## Communication task 1 – hygiene/therapy

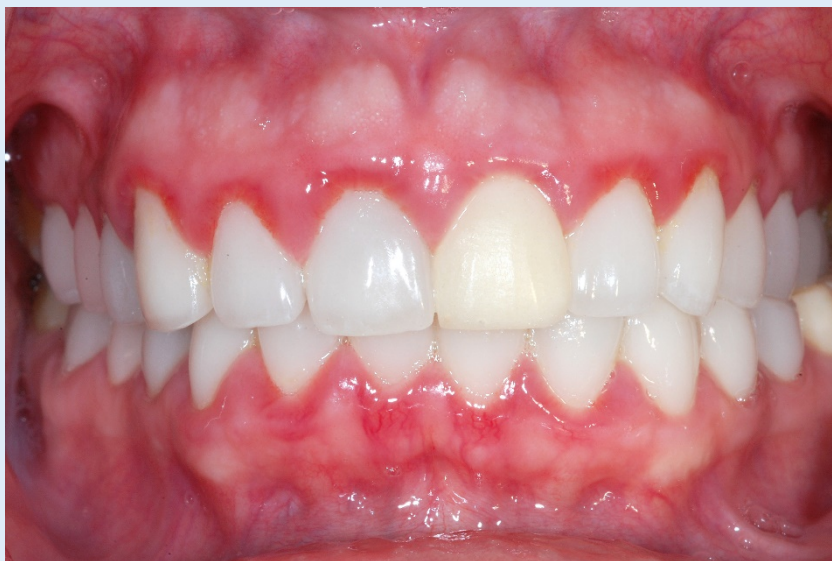Miss Shaye Watson is a 16 year-old patient who has been referred to you by the principal dentist in your practice.

Shaye's history indicates that she has been an irregular attender in the past and has missed a number of her scheduled recalls. Shaye has never seen another dental professional as her parents are close family friends with the principal dentist.

The dentist has asked you to see Shaye today as he has noticed an overall decline in Shaye's oral hygiene. The clinical notes indicate inflamed gingival margins, widespread bleeding on probing and a moderate amount of calculus present with associated plaque retention. You only have 10 minutes for the appointment and are fully booked for the rest of the day.

**You should aim to discuss the decline in Shaye's oral hygiene and to plan subsequent appointments to address the clinical situation. (You do not need to perform a clinical examination during this task).**

**You have 10 minutes for this consultation. You should guide the consultation towards obtaining consent for your suggested treatment plan.**



An examiner will escort you into your surgery and will observe the consultation.

A second examiner will be acting as the patient and will occasionally ask you a question. You should assume that they are a regular dental patient with limited dental knowledge. You should speak to them as a patient and not as an examiner with expert dental knowledge.

You will be reminded when there is one minute left before the end of the task and you should then close the consultation appropriately.

## Communication task 2 – Dental Hygiene

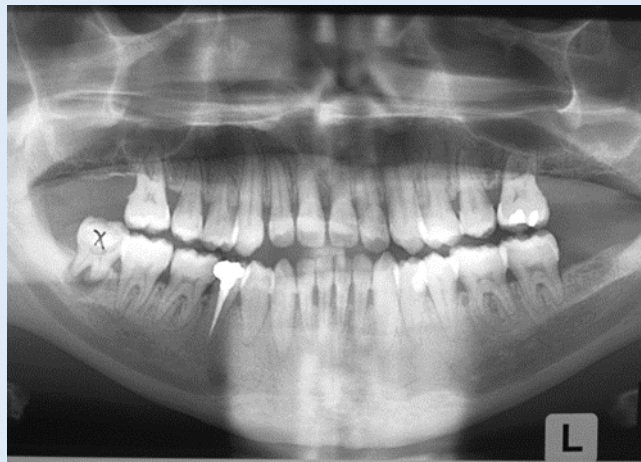
Mrs Wilson is 45 years-old and is a new patient to your practice.

She attends today requesting a scale and clean as her previous dentist of 20 years has recently retired.

Your principal dentist has completed a preliminary examination, but has referred Mrs Wilson to you for periodontal assessment and consultation.

You note that Mrs Wilson's medical history is clear but she reports that she smokes 10 cigarettes a day and has a family history of early tooth loss.

Mrs Wilson has brought along an orthopantomograph (OPG), taken at her last dental appointment where she had tooth 48 extracted.



Today, you have performed a full periodontal examination including periodontal charting. You find heavy plaque and calculus deposits and extrinsic staining, with some bleeding on probing at deeper sites. You record generalised probing depths of 5-6mm and recession of up to 2mm on the lower anterior teeth.

You diagnose generalised chronic moderate periodontal disease, with some localised severe sites.

**You have 10 minutes for this consultation.**

**Explain your diagnosis to Mrs Wilson and work towards gaining informed consent for your periodontal treatment plan.**

An examiner will escort you into the consultation room and will observe the consultation.

A second examiner will be acting as your patient and will occasionally ask you a question. You should assume that they are a regular dental patient with limited dental knowledge. You should speak to them as a patient and not as an examiner with expert dental knowledge.

You will be reminded when there is one minute left before the end of the task and you should then close the consultation appropriately.